
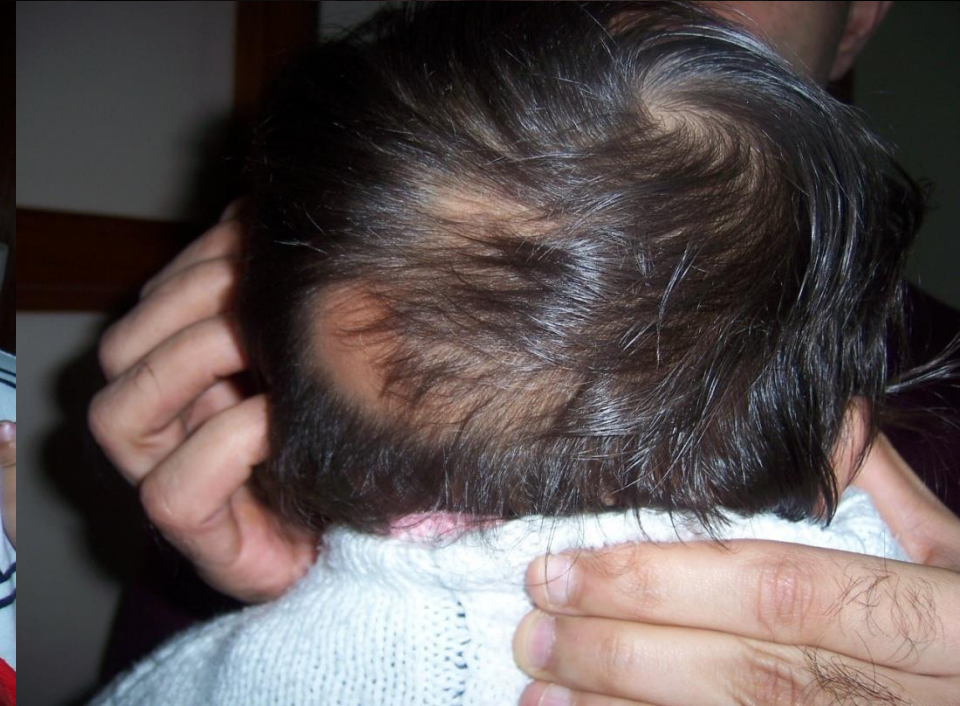
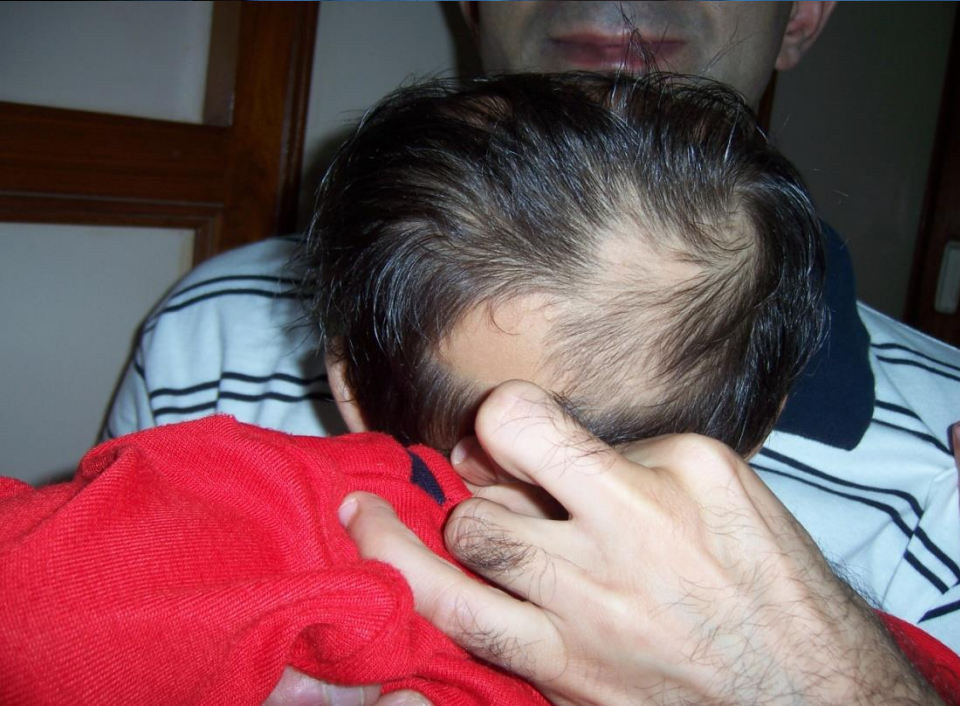
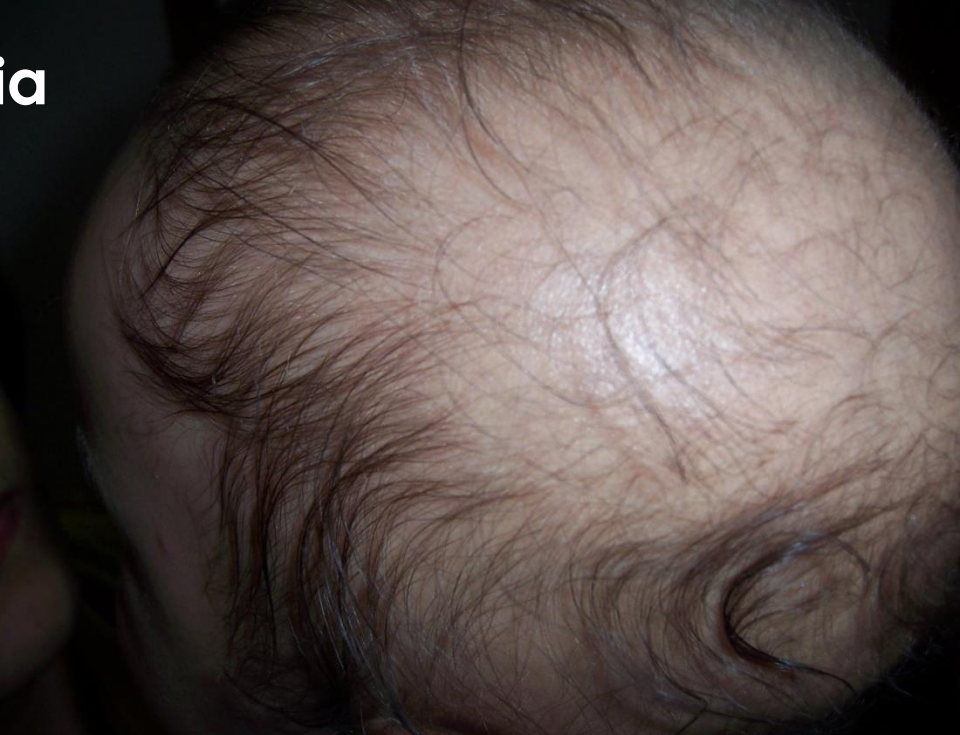
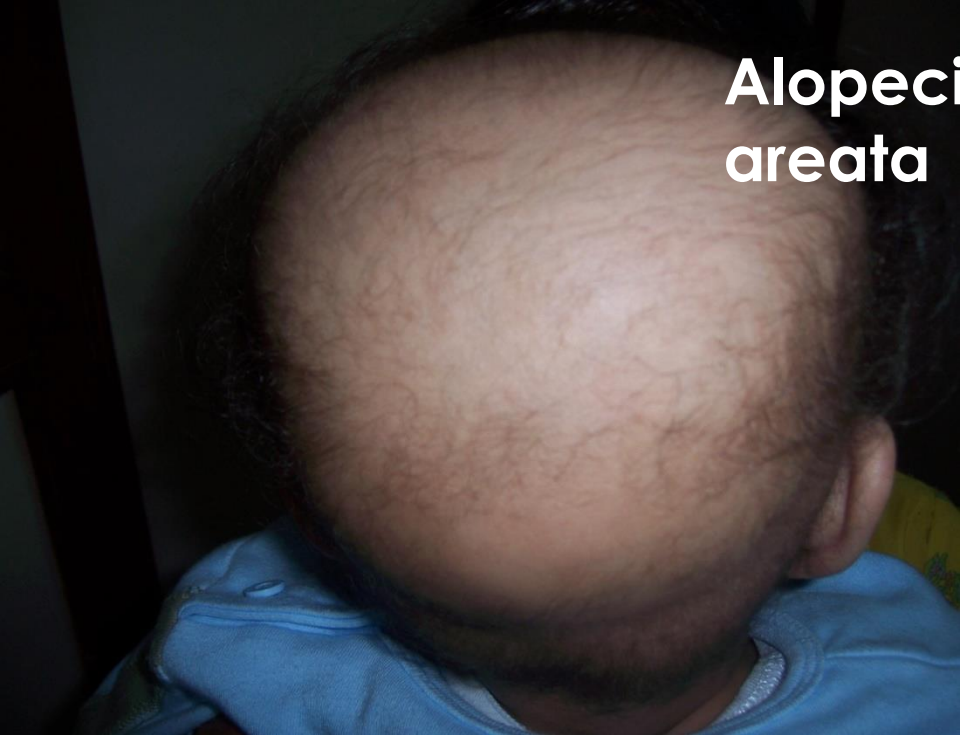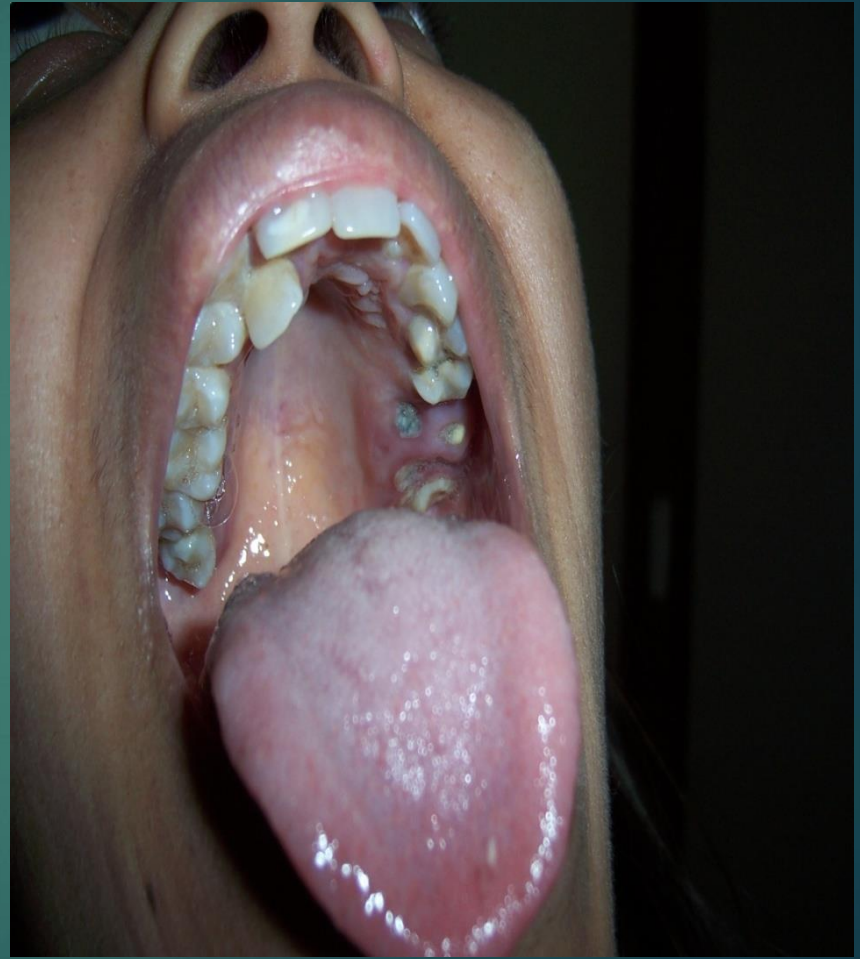
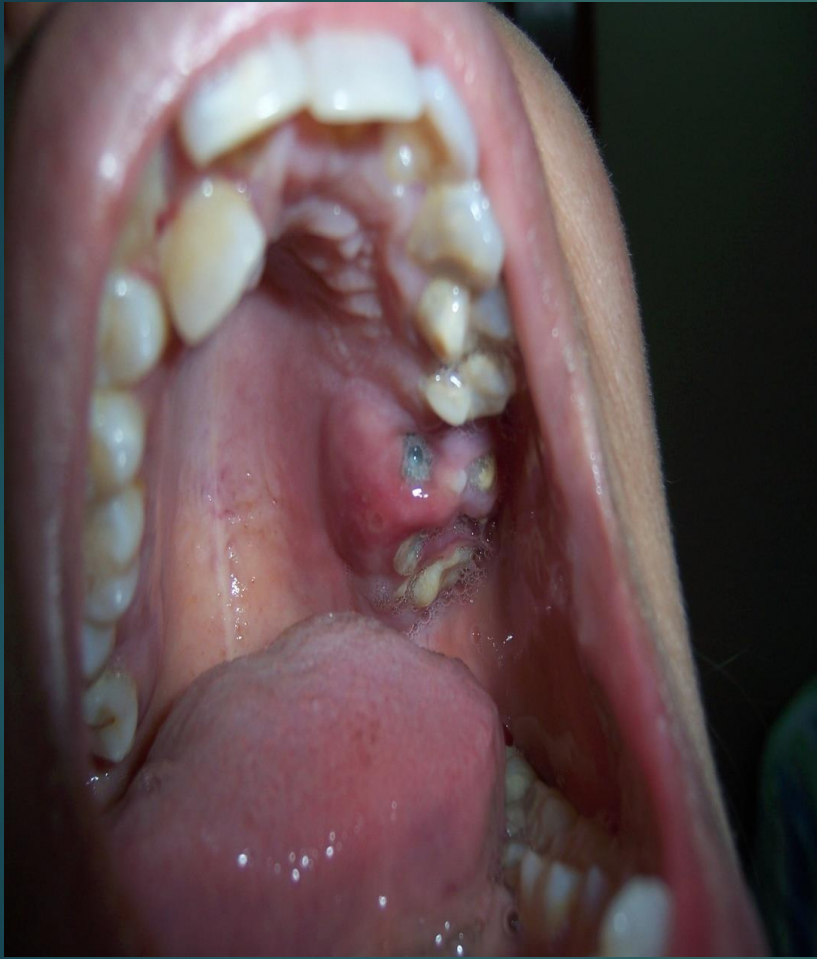Glimpse of Patient Cases

DR. ARUN SATIJA

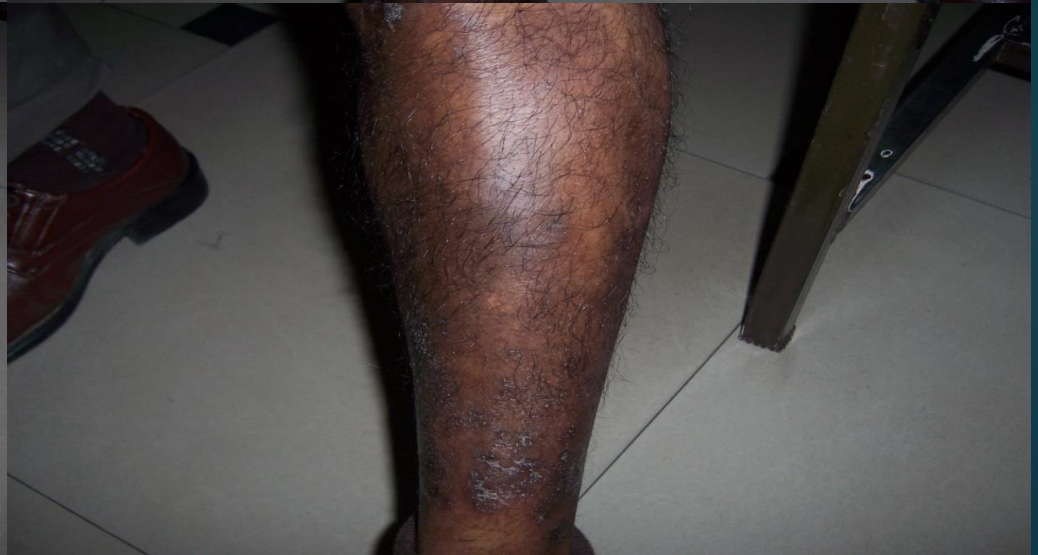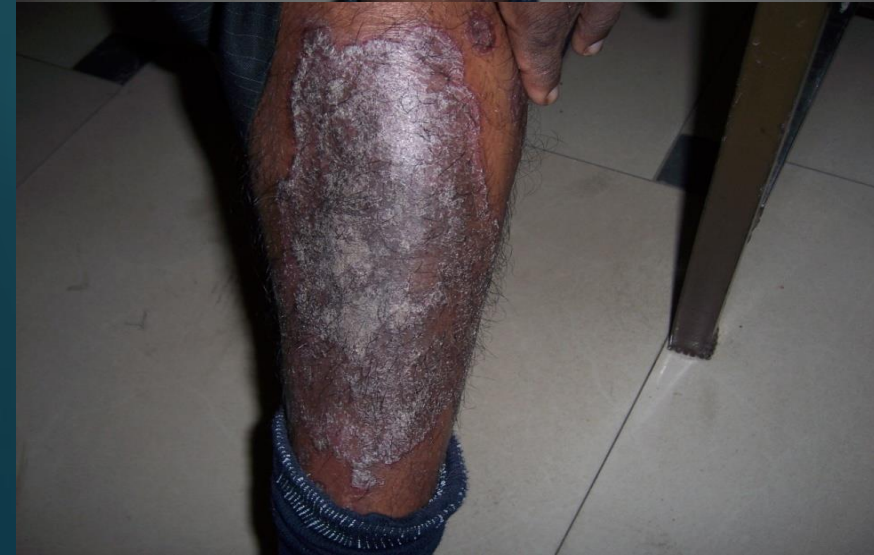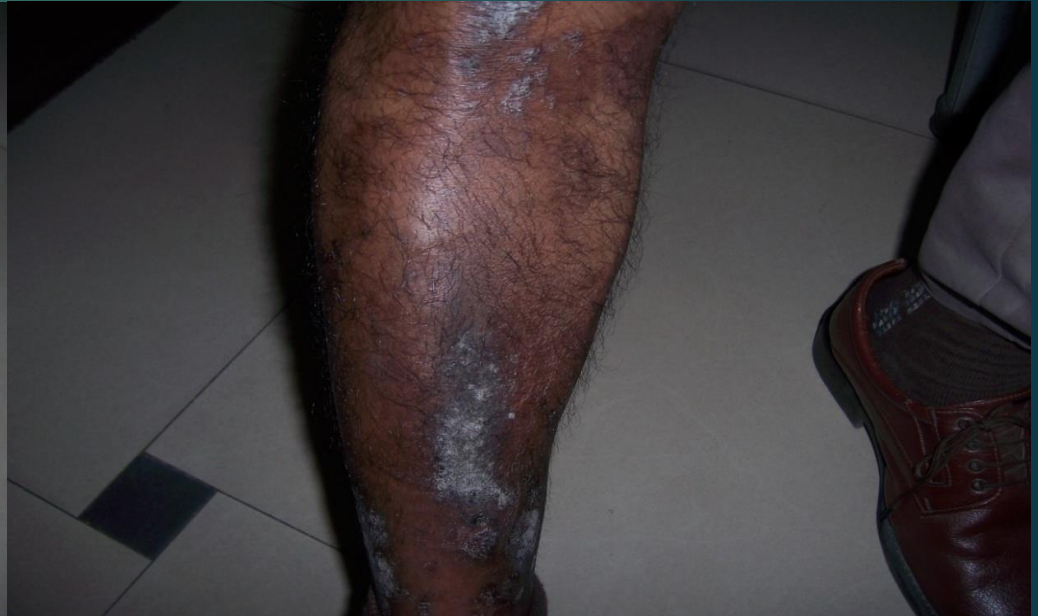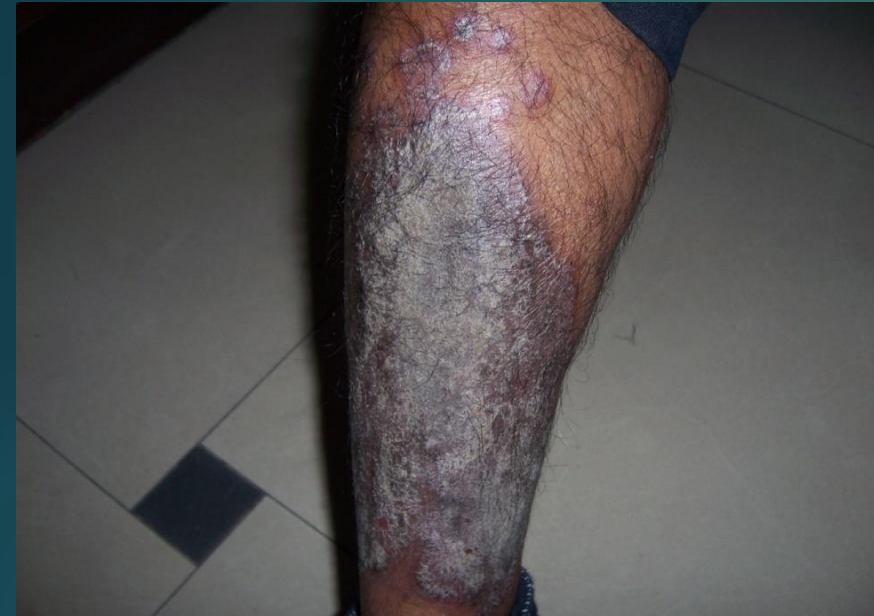Alopecia areata



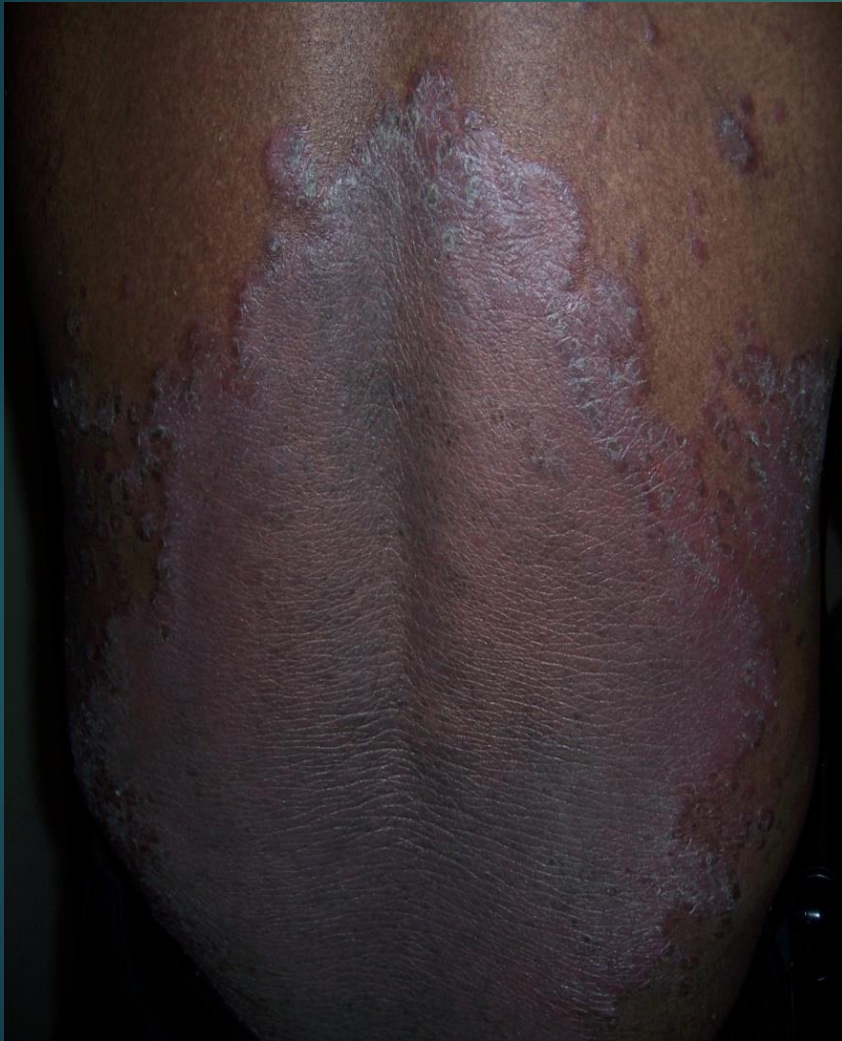Carious Infected Teeth



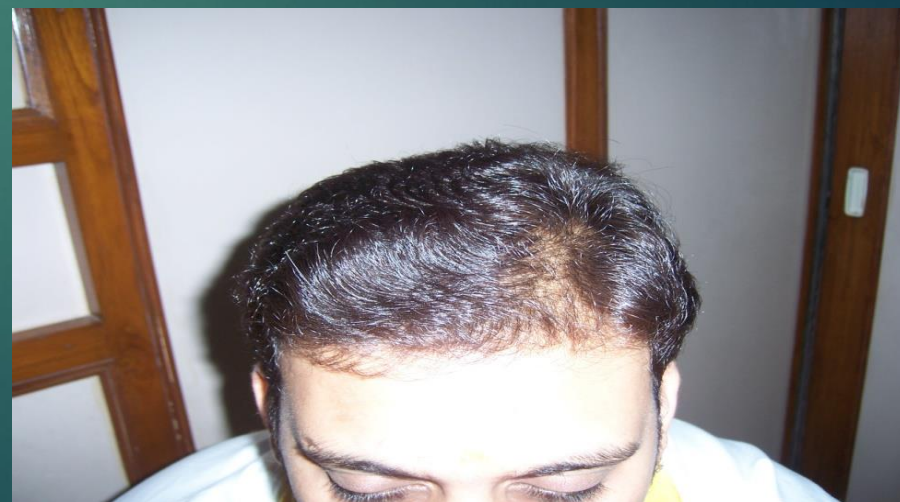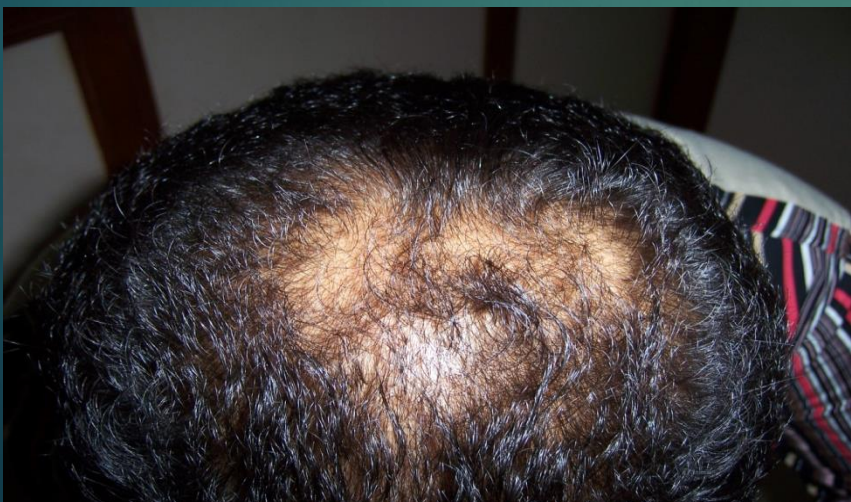
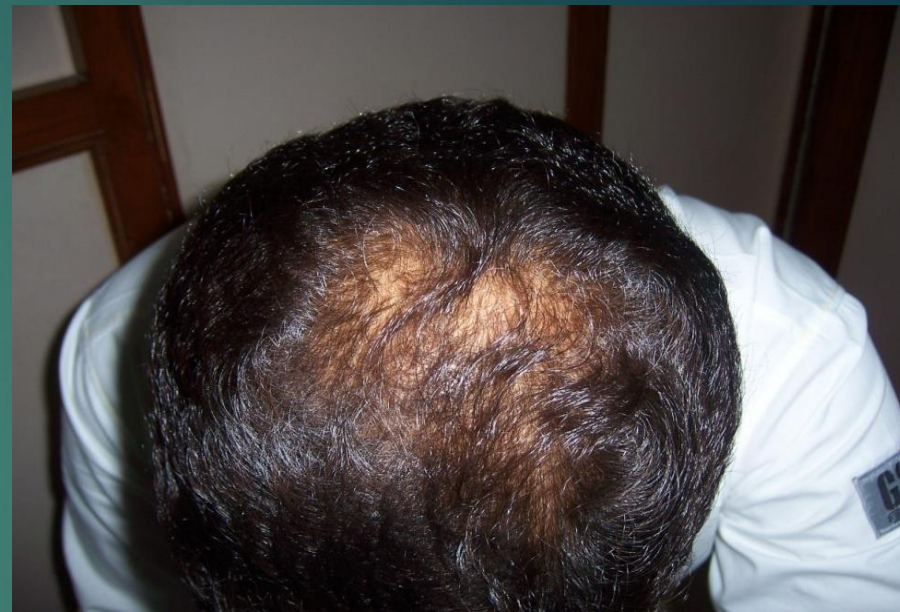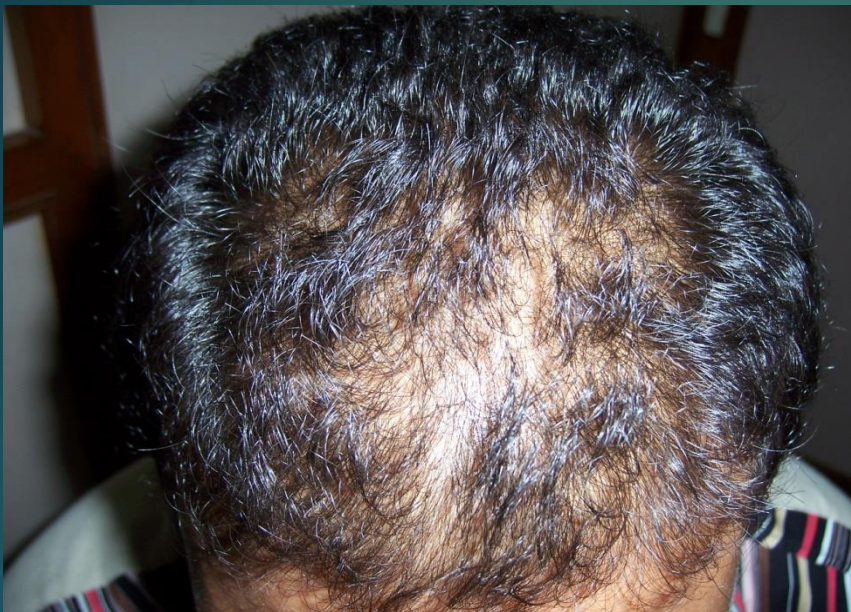Psoriasis



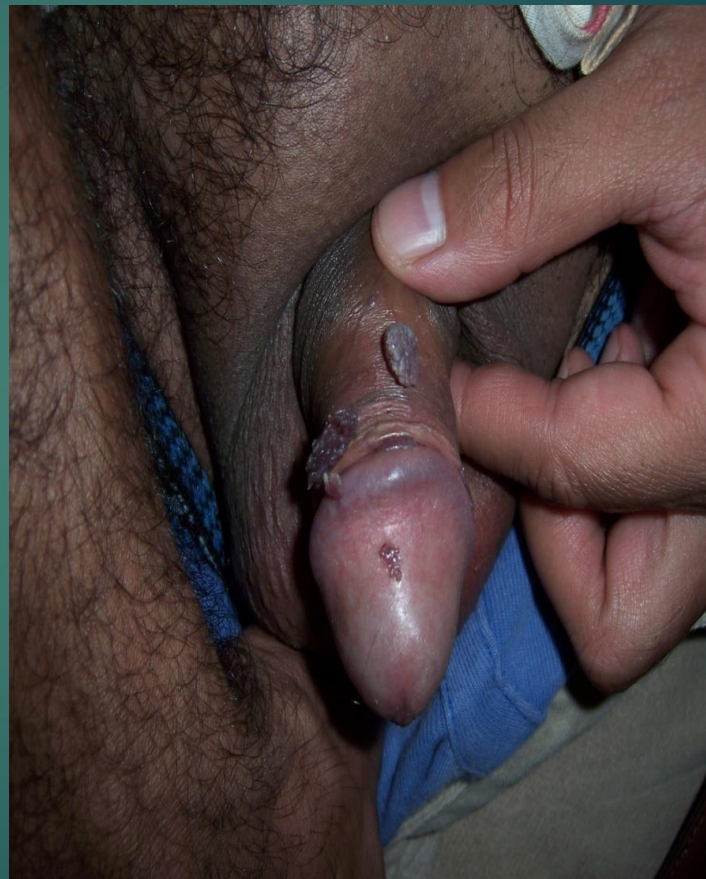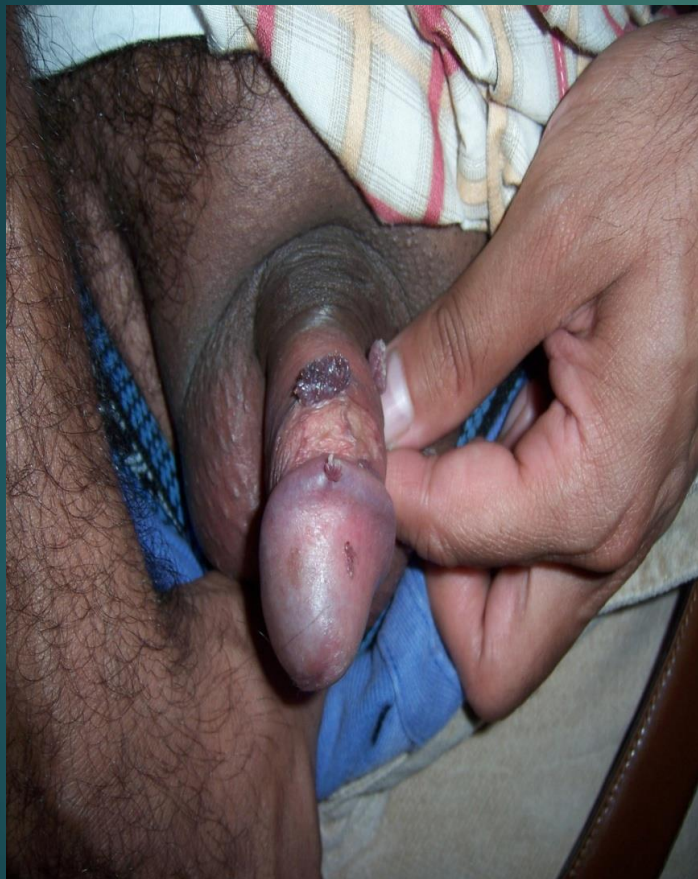Psoriasis



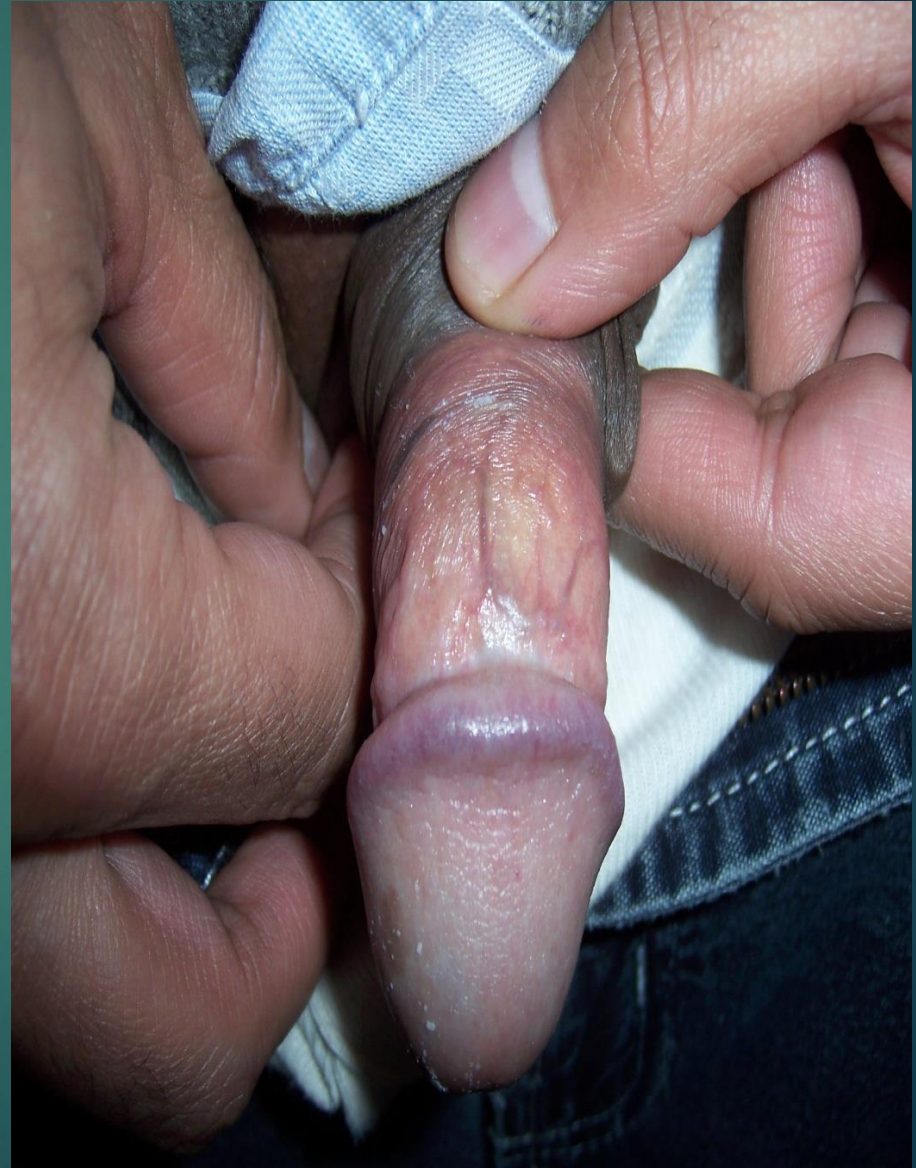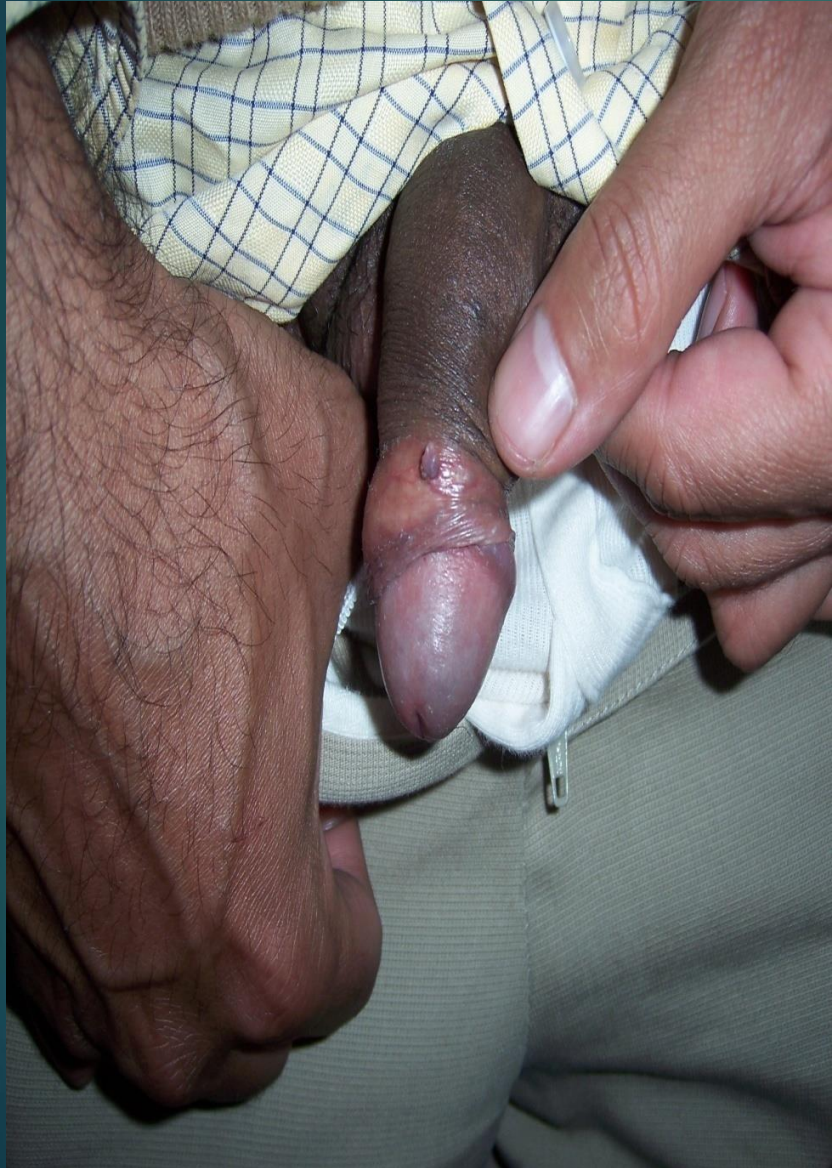Post Typhoid Alopecia



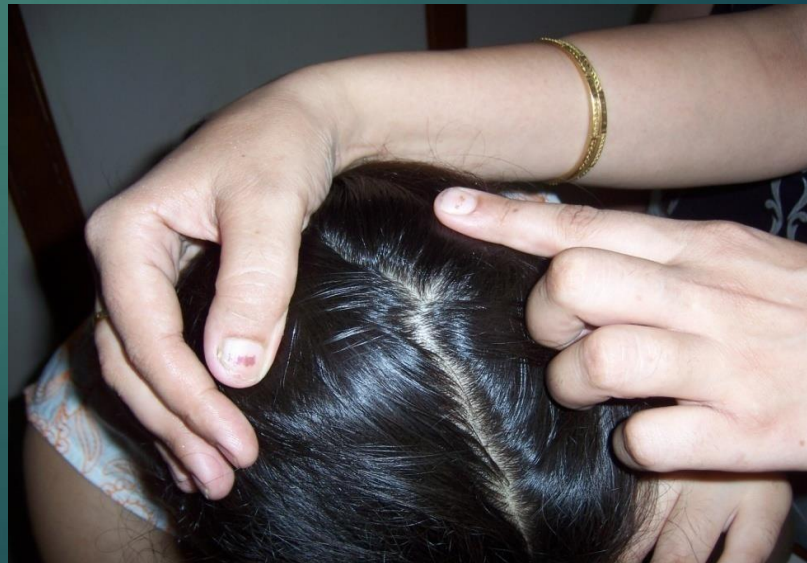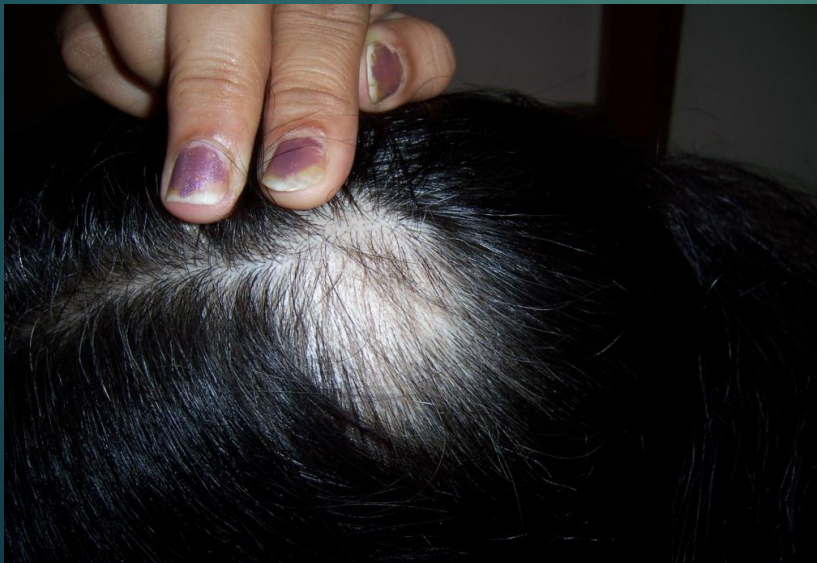
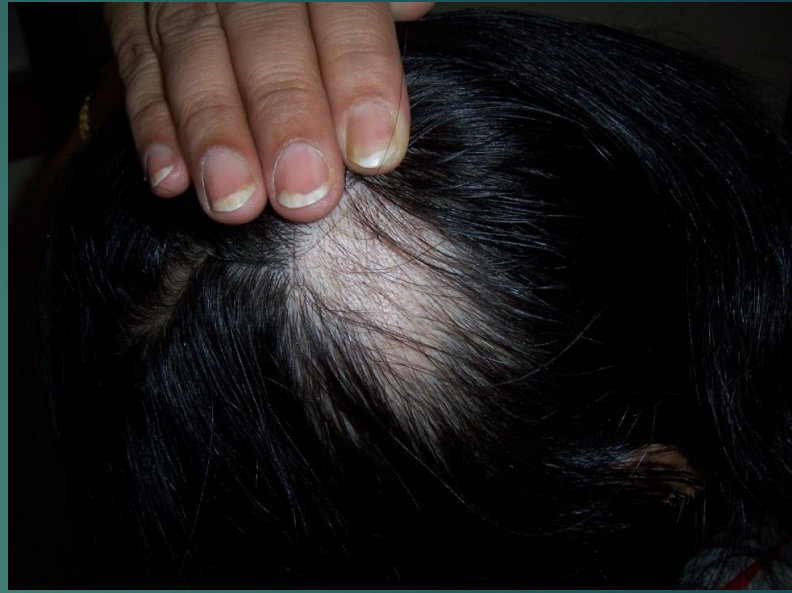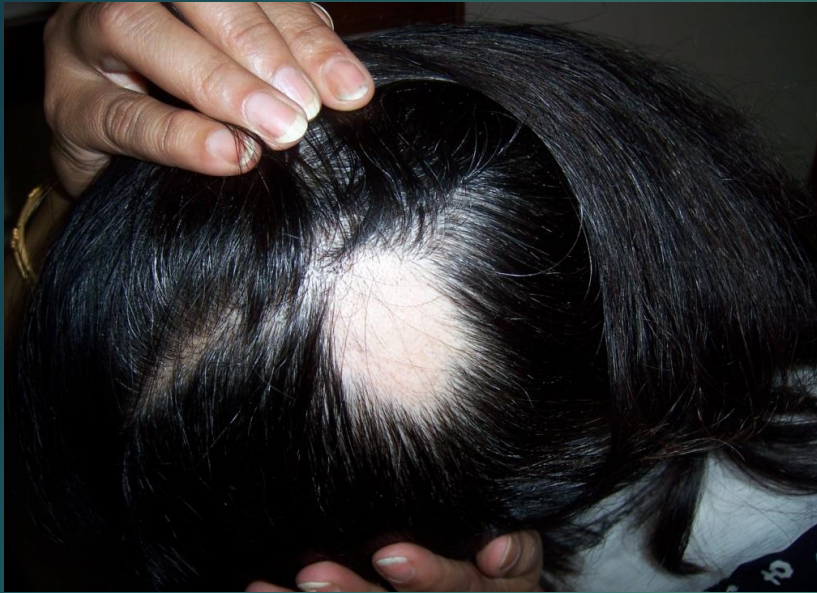Genital Warts



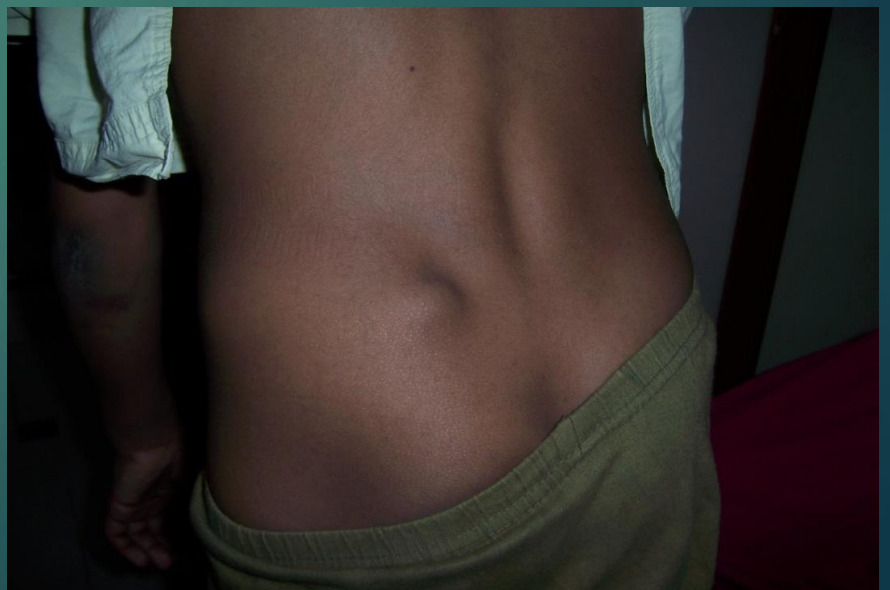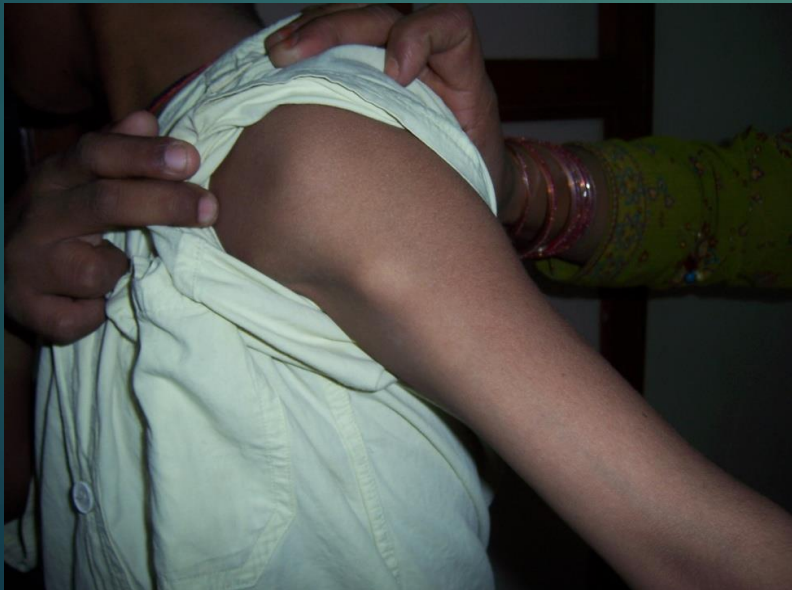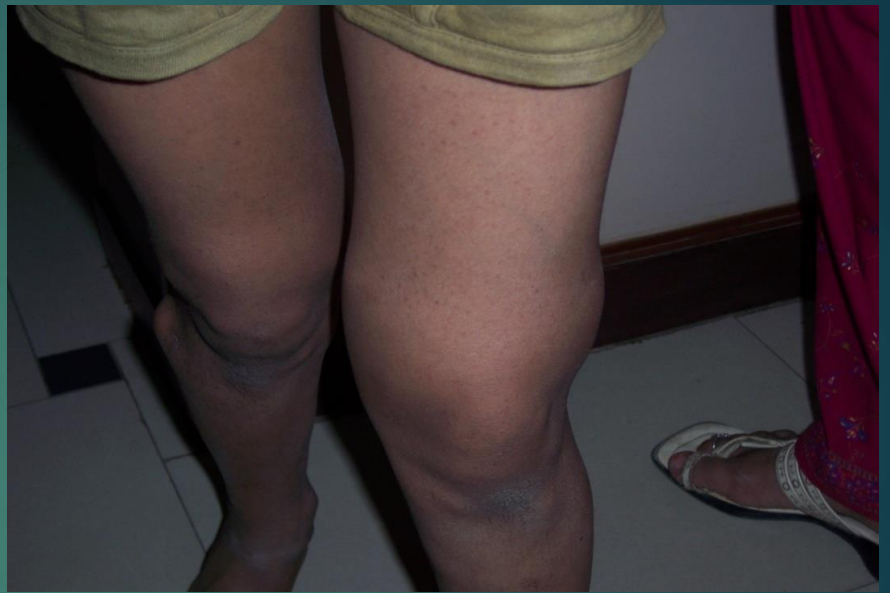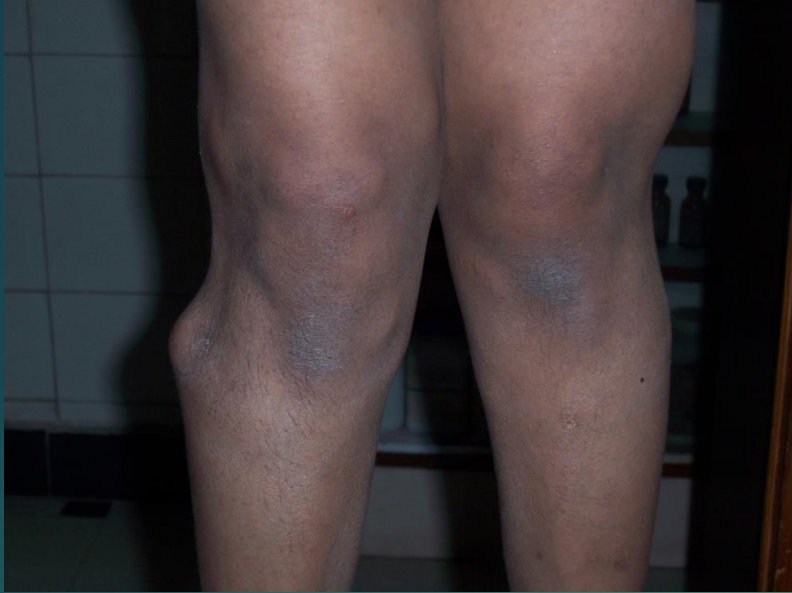Genital Warts



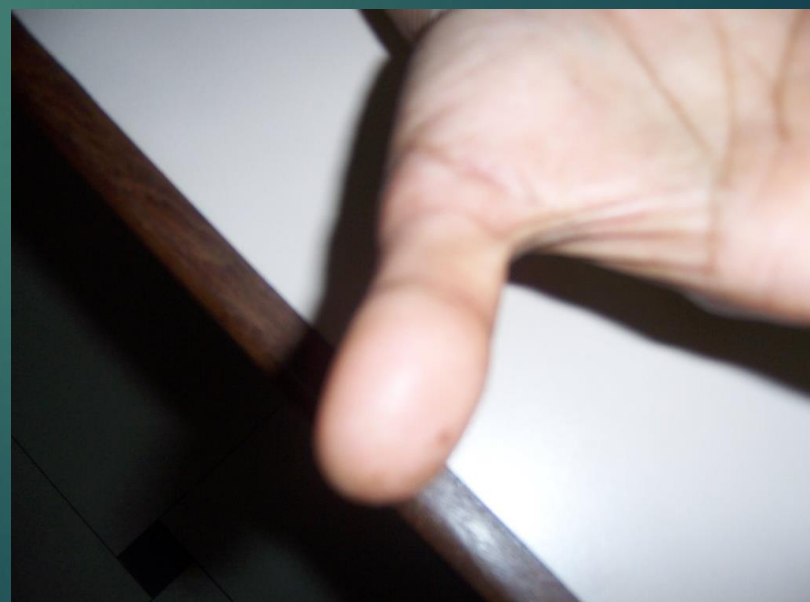
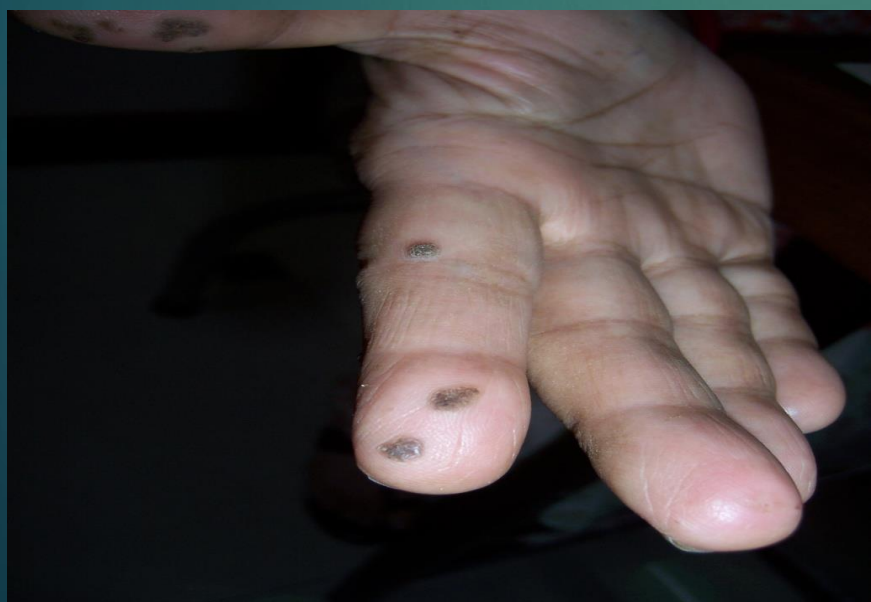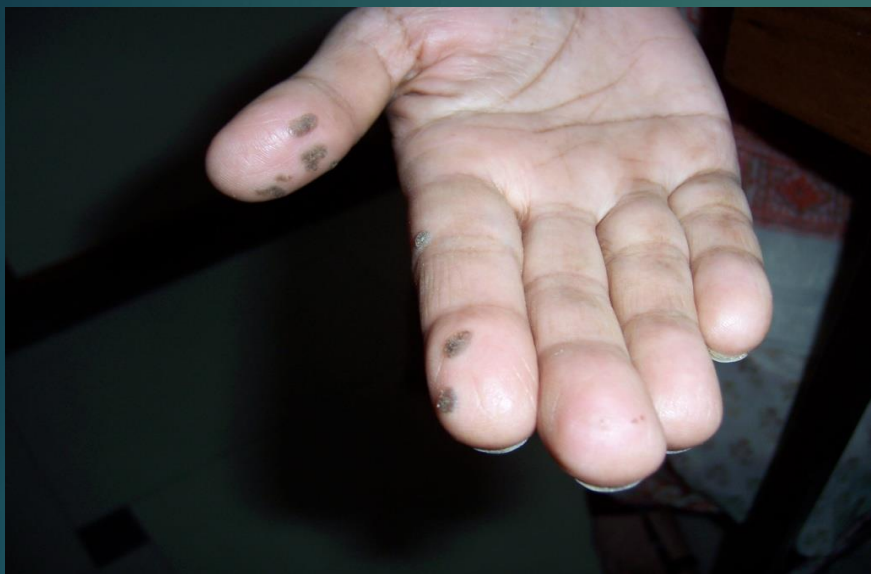Alopecia Areata



Multiple Exostosis



Planter Warts



Pilonidal Sinus

